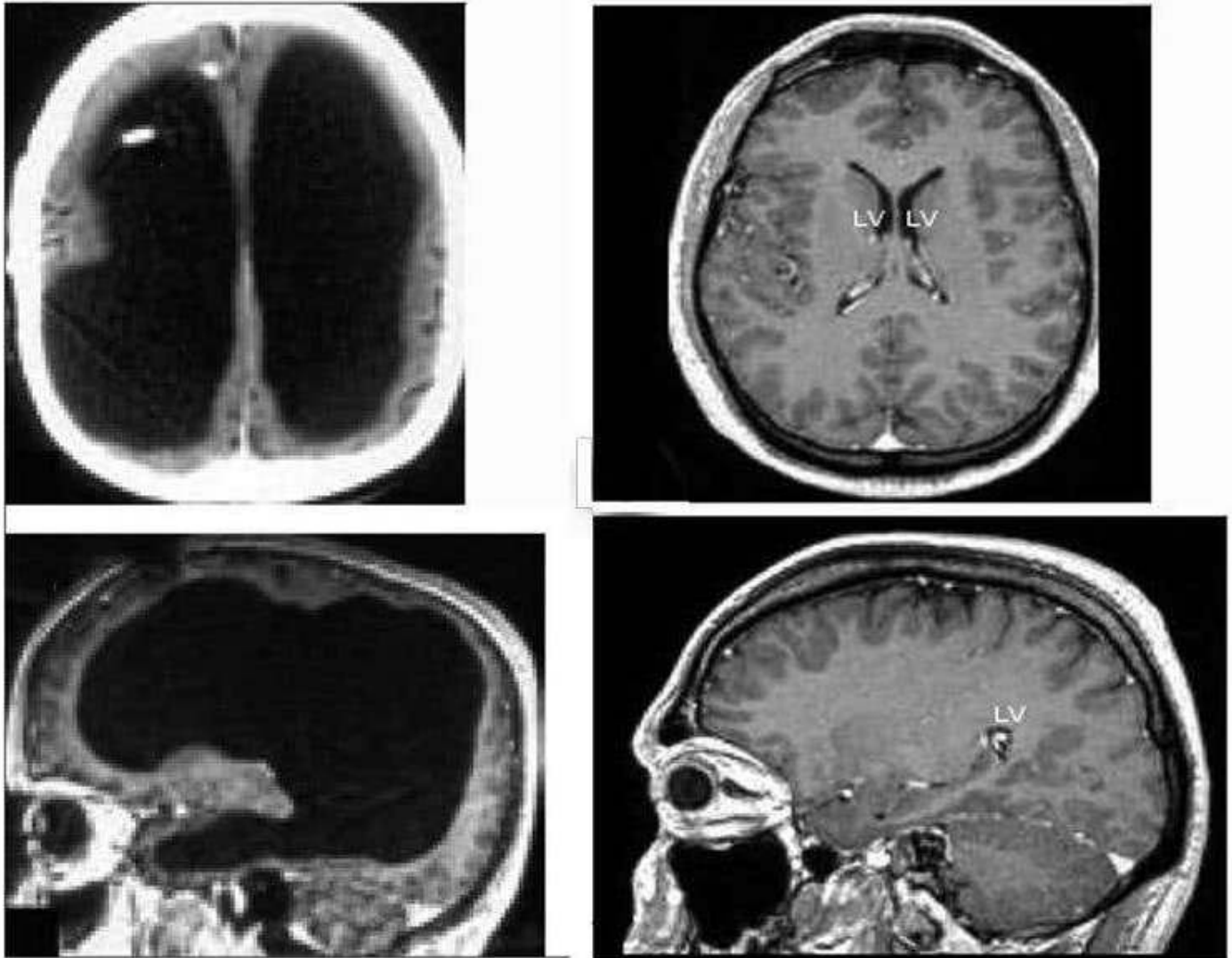


Man with tiny brain shocks doctors

By [New Scientist](#)

📅 20 July 2007



▲ **The large black space shows the fluid that replaced much of the patient's brain (left). For comparison, the images (right) show a typical brain without any abnormalities**

Feuillet et al./The Lancet

A man with an unusually tiny brain manages to live an entirely normal life despite his condition, which was caused by a fluid build-up in his skull.

Scans of the 44-year-old man's brain showed that a huge fluid-filled chamber called a ventricle took up most of the room in his skull, leaving little more than a thin sheet of actual brain tissue (see image of the patient's brain, above left).

"It is hard for me [to conclude] the percentage of reduction of the brain since we

“It is hard for me [to say] exactly the percentage of reduction of the brain, since we did not use software to measure its volume. But visually, it is more than a 50 to 75 per cent reduction,” says Lionel Feuillet, a neurologist at the Mediterranean University in Marseille, France.

Feuillet and his colleagues describe the case of this patient in *The Lancet*. He is a married father of two children, and works as a civil servant.

‘Massive enlargement’

The man went to a hospital after he had mild weakness in his left leg. When Feuillet’s staff took his medical history, they learned that, as an infant, he had had a shunt inserted into his head to drain away hydrocephalus – water on the brain.

The shunt was removed when he was 14. But the researchers decided to check the condition of his brain using computed tomography (CT) scanning technology and another type of scan called magnetic resonance imaging (MRI). They were astonished to see “massive enlargement” of the lateral ventricles – usually tiny chambers that hold the cerebrospinal fluid that cushions the brain.

[“Read: Woman of 24 found to have no cerebellum in her brain !\[\]\(339a16584d5da0f0a3ca4e9ec17bf6a1_img.jpg\) /article /mg22329861-900-woman-of-24-found-to-have-no-cerebellum-in-her-brain/”](#)

Intelligence tests showed the man had an IQ of 75, below the average score of 100 but not considered mentally retarded or disabled.

“The whole brain was reduced – frontal, parietal, temporal and occipital lobes – on both left and right sides. These regions control motion, sensibility, language, vision, audition, and emotional and cognitive functions,” Feuillet told *New Scientist*.

Brain adaptation

The findings reveal “the brain is very plastic and can adapt to some brain damage occurring in the pre- and postnatal period when treated appropriately,” he says.

“What I find amazing to this day is how the brain can deal with something which you think should not be compatible with life,” comments Max Muenke, a paediatric brain defect specialist at the National Human Genome Research Institute in Bethesda, Maryland, US.

“If something happens very slowly over quite some time, maybe over decades, the different parts of the brain take up functions that would normally be done by the part that is pushed to the side,” adds Muenke, who was not involved in the case.

For more stories about people with extraordinary brains, including [the first interview with a dead man](#) [/article/dn23583-mindscapes-first-interview-with-a-dead-man/](#), see our [Mindscapes](#) [/article_type/mindscapes/](#) column.

Journal reference: [The Lancet](#) <http://www.thelancet.com> (vol 370, p 262)